

Dental Distress

The 'Diving Dentist' Addresses the Problem of a Diving-Related Toothache

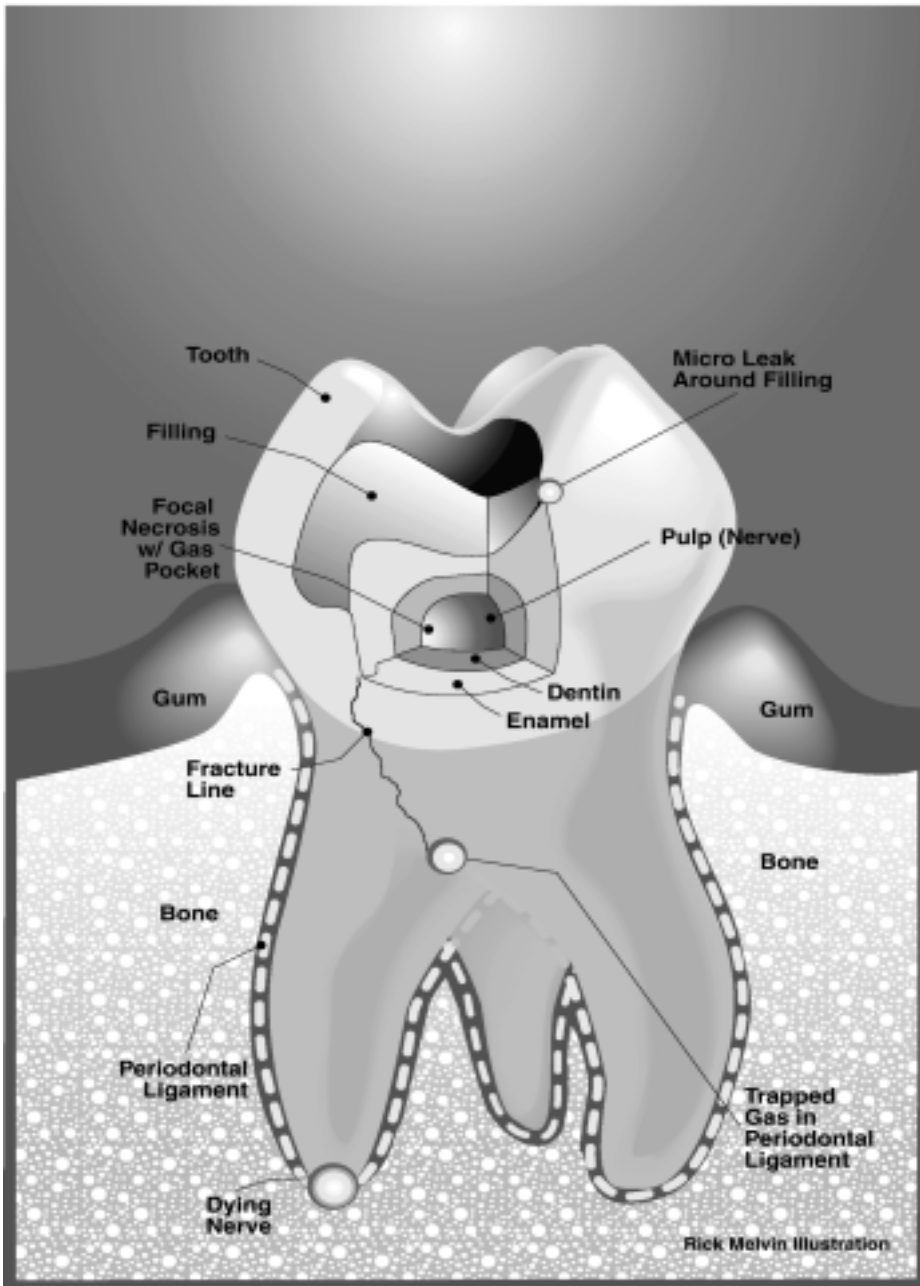
By Laurence Stein,
DDS

Although not a common ailment in scuba diving, tooth pain can be a troublesome side effect of our sport. Whether it's a problem with your bite on the regulator, an incidence of tooth squeeze or a broken, chipped or cracked tooth, you need answers. And finding a dentist who knows the literal pressures of scuba diving is a real plus!

Dear DAN,

My husband and I thought it would be a good idea to join DAN when we were planning a dive vacation to Belize. I never thought I would need it, but "better safe than sorry, right?" Well, I'm writing to tell you about the best \$46* I have ever spent and why my DAN card is the one I "won't leave home without."

I am a marine biologist with a local government agency. My job requires me to spend about three days a week diving off the coast of Florida. (I know - it's a tough job.)



The indicated areas are possible sources of gas trapping and pain. It is unlikely that all the areas would be affected in any single incident, however.

Gas trapped in a dead nerve space diffuses more slowly because of the lack of vasculature. The periodontal ligament is well-supplied with a blood supply and should diffuse more rapidly. Gas trapped in a fracture near either a vital or non-vital nerve could cause pain for a variable period of time.

Occasionally, leaky fillings or fractures may act like one-way valves: the gas gets in much easier than it can get out.

* for DAN's Master Plan dive accident insurance, available with DAN membership.

Tooth Pain Going Down

My encounter with DAN started a few months ago after a visit to my dentist for a routine filling. A week later, I made my first dive with my "new" tooth. When I descended to 3 metres, I felt a pain in the area of that tooth.

I attributed the pain to cold sensitivity from the nitrox in my cylinder and continued my descent. The pain did not increase, and I spent approximately 40 minutes at 15 metres and began my ascent.

More Pain Coming Up

As I ascended, the pain became concentrated in that one tooth and got worse as I neared the surface. I did not dive for the rest of the day, and gradually the pain went away. I suspected I had air trapped in the tooth, and I contacted my dentist that afternoon.

X-rays of the tooth did not show air pockets, according to the dentist: instead, he suspected a sinus infection or minor cold symptoms.

Scuba diving is an essential part of my job, and, since I had never experienced that type of pain in almost 1,000 dives, I requested that the filling be replaced. This seemed to resolve the problem, and I continued diving with no pressure-related pain

Sensitivity to Heat & Cold

Later, however, I began experiencing extreme hot and cold sensitivity in that tooth. This persisted for about a month, prompting trip #3 to the dentist. This time he coated the tooth with a sealant to reduce its sensitivity.

After a week I reported to his office for the fourth time, with no change in symptoms. He replaced the filling one more time, and I left his office numb but happy, positive that we had finally solved the problem.

More Pain When Diving

Two days later, I attempted my next dive. On descent to about 9 metres, the pain was back, this time worse than ever. I immediately signaled to my buddy to abort the dive, and I began an extremely slow ascent. When I was 3 metres from the surface, the pain became unbearable. I literally gritted my teeth and managed to get back to the boat.

Now it felt as if the entire left side of my face was going to explode, and we headed back to the marina. It took about four hours for the pain to go away.

Call DAN

Determined to get an answer, I called DAN's Medical Line and spoke with DAN Diving Medic Dan Nord. He recalled an article written for Alert Diver magazine by Laurence Stein, DDS, that addressed barodontalgia, or tooth squeeze. Could this be the answer?

Mr. Nord forwarded a copy of the article via e-mail for me to read. Coincidentally, the author was a dentist whose office was located about 20 minutes from my house.

I immediately made an appointment with Dr. Stein: he fit me into his schedule the very next day. His examination revealed I was suffering from a crack in my tooth, which allowed air to enter and expand or contract with changes in pressure. He recommended that I see a specialist for a root canal and then have the tooth crowned to eliminate any pathway for air to enter.

I followed his advice, and although I wasn't exactly thrilled to spend the required hours in the chair and listening to Muzak, I think my problems have been solved. It has been about six weeks since I saw the "diving dentist," and I don't know who is happier - me or my co-workers (they were working double shifts while I was out of commission.).

- A DAN Member in Miami, Fla.

Dr. Stein's Assessment

Getting to the Root of the Problem

When this diver came into my office, her medical questionnaire indicated that she sometimes had sinus headaches and that she had frequent headaches after dives. This medical history, combined with the number of replacement fillings she had had, initially made me skeptical that she had barodontalgia, or tooth squeeze, a logical initial assessment of a scuba diver with a toothache. The most common source of dental pain from barometric pressure is, in fact, caused by the maxillary sinuses.

I examined the diver, and found her tooth was very sensitive to cold air. I then had her put pressure on her tooth with a *Fracfinder*, a device used specifically to test dental bite pressure. The upper-left first molar reacted to both the applied pressure and rebound sensitivity (pain on release of pressure).

Transillumination with a high-intensity light revealed a vertical fracture line on the side of the tooth. X-rays showed several radiolucent areas associated with the apices (the ends of the roots) of the tooth, an indication of a damaged nerve within the tooth. (A radiolucency is a radiographic image that is darker than the surrounding structures. When they occur at the ends of the roots, it raises suspicion that the nerve within the tooth is dead or dying.)

She also had joint noises from the jaw, indicating a probable tendency to grind her teeth. Often, such patients unconsciously grind their teeth at night, increasing the chance of fractures, broken teeth and fillings and muscular pain.

My clinical impression was that she had irreversible pulpitis (inflammation to the pulp of the tooth) with a fractured tooth. I advised her to see a root canal specialist and asked her to keep me updated.

Questions

Going back to the diver's first visits to her dentist, did the previous drillings she experienced when she had her fillings replaced help cause the crack in her tooth?

It's not really possible to determine whether the procedures her tooth was subjected to could have also contributed to the crack in her tooth. It is possible for the shock wave generated by the high-speed drill to cause or propagate a fracture. The drill also generates frictional heat, and this can injure a tooth nerve -

that's why the drill sprays so much water during dental treatment.

My suspicion is that the fractures in this diver's tooth may have pre-existing because they occurred in the grooves that naturally occur on the surface of a tooth. These grooves create weak spots and, if there is a large filling in a tooth, the remaining tooth structure containing the filling may be as thin as an eggshell. Each time the tooth is worked on, slightly more tooth structure is removed, and the tooth gets weaker. A tendency to grind one's teeth will exacerbate the problem as well.

The tooth contains a nerve canal, comprised of blood vessels, nerves and connective tissue. When the tooth is injured or when bacteria are trapped within the chamber, pressure begins to build. When the internal tooth pressure exceeds blood pressure, blood flow in that area essentially ceases: removal of blood, nutrients, oxygen or carbon dioxide cannot occur. The endodontist, or root canal specialist, performs a root canal procedure to vent the pressure and remove the dead nerve.

The more insults (fillings, fractures,

clenching) a tooth undergoes in its lifetime, the greater the chances that a problem will occur. This is actually what happened to this diver. When I saw the tooth, it had a fracture in it, possibly allowing bacteria into the nerve area. The diver's dentist followed the book in treating her, yet conservative treatment was not effective in this case.

By the time I saw her, the nerve in her injured tooth was partially dead, with a compromised blood supply. Increased pressure during scuba diving allowed the accumulation of gases into tissues that no longer had a good blood supply to help eliminate the gas build-up. The result was an expansion of the tooth through the fracture line - and pain.

KANGAROO ISLAND
SOME OF THE MOST EXCITING SCENERY
BOTH BELOW AND ABOVE THE WATER,
ANYWHERE IN AUSTRALIA

PHOTO: GREG ADAMS

MEALS ♦ ACCOMMODATION ♦ FULL GEAR HIRE IF BOOKED

For information about diving and holidaying on this unique remote location, contact:
KANGAROO ISLAND DIVING SAFARIS
TOURING • FISHING HOST FARM

JIM & JOSIE THISELTON,
TELHAWK, C/O KINGSCOTE,
KANGAROO ISLAND 5223,
PH/FAX: (08) 8559 3225
Email: kids@kin.on.net
Internet: <http://kiddivingsafaris.com>

The Crowning Touch

Final treatment on this diver's tooth consisted of a root canal, a post and core to fill the chamber and a crown to strengthen the fractured tooth by an endodontist. Normally, a root canal is completed in stages. First, the endodontist makes a hole or access opening through the top of the tooth until the nerve chamber is exposed. Then he evaluates the vitality of the contents of the nerve chamber as well as the amount of bleeding, if any.

Next, he identifies the canals in each of the roots. It is now common to do this with an operating microscope, especially on molars because of the presence of extra canals. He measures the canals in each root and removes the contents of the nerve chamber. He widens the canals so he can introduce instruments into the canals, which can reach to the root ends.

Finally, he fills the canals with a rubbery material called gutta percha, which is heated and compressed into each canal along with a cement or sealer to block the collection of fluids in the canals.

Once the canals are filled, it is common for the endodontist to place a piece of cotton in the nerve chamber and cover it with a temporary cement. The patient then returns to the restorative dentist. This usually requires an endopost and core as well as a crown. The cotton placed by the specialist is used as a marker to the restorative dentist when removing the temporary filling. When the drill hits the cotton, we know that the filled root canals are just below.

Because of the delay between the endodontist's work and that of the restorative dentist, divers awaiting final placement of a crown should avoid both diving and flying. The piece of cotton inserted into the prepped tooth prior to a crown can become a liability if the person participates in some activity which results in a change in air pressure.

Another way to avoid this pressure problem is to ask the specialist to fill the entire chamber with a strong cement. This avoids the cotton and the resultant air space. This patient had the root canal and a cement core completed by the root canal specialist - all that remained was placement of the crown.

Background

So, what should we as divers expect from our teeth? If we have fillings, are we likely to experience barotrauma, tooth cracks or worse? Let's take a look at the ingredients of different fillings.


Fillings

Silver is a cost-effective tooth filling: it doesn't take long to place these fillings, and they usually last a long time. Published estimates of the life expectancy of a silver filling show they are supposed to last seven to 10 years. This range reflects the ideal filling with no breakdown, corrosion or chipping at the edges.

Realistically, however, most people have fillings that were placed when they were children, and they remain serviceable today. These fillings may be black in colour, the tooth may be discolored and the edges are commonly chipped. Sometimes the adjacent tooth structure has formed small chips. At some point in the lifespan of a filled tooth, the silver will have to be replaced with a larger filling or even a crown.

Silver Fillings - No Silver Linings

Silver has some properties that make it less than ideal for tooth fillings. Despite its low cost, many dental experts feel that silver fillings have certain physical properties that can put teeth at future risk for recurrent decay, fractured teeth and sensitivity.



DIVE VICTORIA Victoria's Safest, Most Professional Dive Charter Operator

Simply the best dive boats... 'Seaquest' & 'Divequest'... Dive our famous Subs and many other wrecks. Experience our unbelievable Walls and fast drift dives. Swim with seals, catch a cray, have a feed of scallops or abalone. Undercover change area. HOT showers and accommodation. Nitrox fills and fire cylinders available.

• Call us at Portsea on (03) 5984 3155 •